

Effectiveness of Stem cell Therapy in Autism Spectrum Disorders: Case Study of Identical Twins

K Sandhya^{1*} and H C Shobha²¹Department of Speech Language Pathology, JSS Institute of Speech and Hearing, India²Department of speech pathology and audiology, JSS Institute of Speech and Hearing, India

Abstract

Autism Spectrum Disorders (ASDs) is a neurodevelopmental disorder with immune system dysfunction. Recent year's researches have exposed importance of cell based therapies which were proposed and applied to ASDs as ASDs are considered to be a Neurobiological condition. Although a few studies show stem cell therapy as an active treatment method for individuals with ASDs there is a lack of empirical evidences to confirm the effectiveness. A twin case study is presented who are diagnosed as having ASDs who had undergone Stem cell therapy treatment. The results of detailed Speech and Language evaluations and other treatments the children had undergone are the focus of present report. Precautions to be taken while choosing the right management option which involves careful parental counseling are discussed.

Keywords: Stem cell therapy; Autistic spectrum disorders; Twin case study

Corresponding author:

Sandhya K, Department of Speech Language Pathology, JSS Institute of Speech and Hearing, India, Tel: 9035362883

✉ gangolibhoomi@gmail.com

Citation: Sandhya K (2021) Effectiveness of Stem cell therapy in Autism Spectrum Disorders: Case Study of Identical Twins. J Child Dev Disord Vol.7 No.8.7

Received: August 03, 2021; **Accepted:** August 17, 2021; **Published:** August 24, 2021

Introduction

Autism spectrum disorders (ASDs) are considered as an interesting neurodevelopmental disorders in the community of medical and scientific research, due to their multifactorial nature and numerous diverse descriptions for their clinical heterogeneity [1]. It is a cluster of developmental disability causes substantial social, communication and behavioral challenges. Currently, the global incidence is 12 per 1000 children [2]. According to DSM-V ASDs can be diagnosed based on these fundamental criteria i.e. Persistent deficits in social interaction and communication, repetitive, restricted patterns of behavior, activities or interests, clinically observable deficit in social, occupational or functioning [3]. More than 1% of the general population is affected by ASDs [4]. Numerous researches have explained the contribution of genetic factors to the occurrence and development of the disorders [5]. Concordance rates among siblings range from about 3% to 14% whereas concordance rate of monozygotic twins has 72% of heritability of having Autism Spectrum Disorders [6].

The management of ASDs can be variable and multimodal. A group of conventional therapies namely early thorough behavior therapy, training on social skills, speech and language therapy, applied behavior analysis (ABA), occupational therapy associated

with psychotropic drugs, transcranial magnetic stimulation [7], and alternative treatments [8], music therapy [9], cognitive and social behavioral therapy [10] have been observed as effective treatment method in the field ASDs. Amongst the advanced therapies available, gene therapy and stem cell therapy have shown abundant potential for treating ASDs [11].

Stem cell therapy, popularly known as regenerative medicine, which involves in the repair of unhealthy, dysfunctional or bruised tissue using stem cells or their derivatives [12]. The important types are fetal/embryonic stem cells, bone marrow derived stem cells/Adult stem cells and Umbilical cord stem cells. Fetal stem cells (FSCs) are found at several stages in the development of a human being which can be obtained and isolated from different somatic organs of fetal blood, fetus, and several embryonic sources such as placenta, amniotic fluid, amniotic membrane, and umbilical cord [13]. Usage of adult stem cells is extracted from bone marrow, skin, dental pulp, adipose tissue and many other sources [14,15].

A study by Sharma A and Gokulchandran N conducted an open label proof of concept of bone marrow mononuclear cells (BMMNCs) intrathecal transplantation in 32 patients with ASDs along with multidisciplinary therapies [15]. Among the patients, 90.6% showed improvement in social relationships and reciprocity,

70% showed improved eye contact, social smile (56%) and so on. 75% of the patients had an improvement in their Speech, language and communications skills which included reduction in echolalia, stereotypic use of language etc. Simultaneously there was a great improvement noticed in behavioural patterns, sensory aspects, cognitive and functional aspects. On the other side 20% of the participants exhibited adverse effects such as increased hyperactivity, increased seizures which were controlled by medications. Another open label pilot study [16] included a total of 45 children with ASDs (39 males, six females, mean age 6.9) where the safety of the use of FSCs were assessed among them. Children with ASDs treated with FSCs displayed improvement in eye contact, appetite, and socialization and exhibited no side effects or adverse events. Irrespective of having numerous studies showing positive effects of Stem cell therapy in the treatment of ASDs, there are also research evidences display adverse effects or no improvement in Speech and Language or behavior of individuals which leads the professional to think over the effectiveness of Stem cell therapy in ASDs.

We present a case of monozygotic identical twins that are diagnosed as having ASDs and were subjected to Stem cell therapy. Details of Speech Language evaluation and their results are presented with specific focus of consequences of Stem cell therapy as a tool in the management in them.

Case Presentation

Twins aged 5.5 years old male, approached JSS institute of speech and hearing, Dharwad with the complaint of limited speech output and behavioral issues. Both the children are known cases of ASDs with the symptoms of delay in language, unusual behaviors such as Hyperactivity, Excessive shouting, head banging, rolling on the floor, fidgeting, vacant staring, hand flapping etc. affected play behavior, low tolerance for sitting and affected social interaction.

Medical history

Children were born as consanguineous union, delivered via c-section at 7th months of pregnancy. Maternal age was 30 years. Mother reported to have low Blood Pressure during delivery. Peri-natal complications included Hypoxia, low birth weight of 1.4 kg due to which they were placed in incubatory for 20 days under observation. They had no history of convulsions. There is no family history of ASD or any psychological illness in the family.

Magnetic Resonance Imaging Diffusion Tensor Imaging (MRI-DTI), and Positron Emitted Tomography Computed Tomography (PET-CT) were carried out to examine the neurological abnormalities. MRI-DTI impressions suggested no focal abnormality in brain parenchyma. PET-CT brain report impression read as bilaterally severely hypo metabolic areas involving medial temporal cortices and cerebellar hemispheres. Electroencephalogram (EEG) showed no evidence of focal or generalized epileptiform activity. Children were born as consanguineous union of parents. This is pedigree chart showing three generations of the family. This displays Autosomal recessive type of gene inheritance with history of twin running in the family, where the marked blocks are the affected twins (Figure 1).

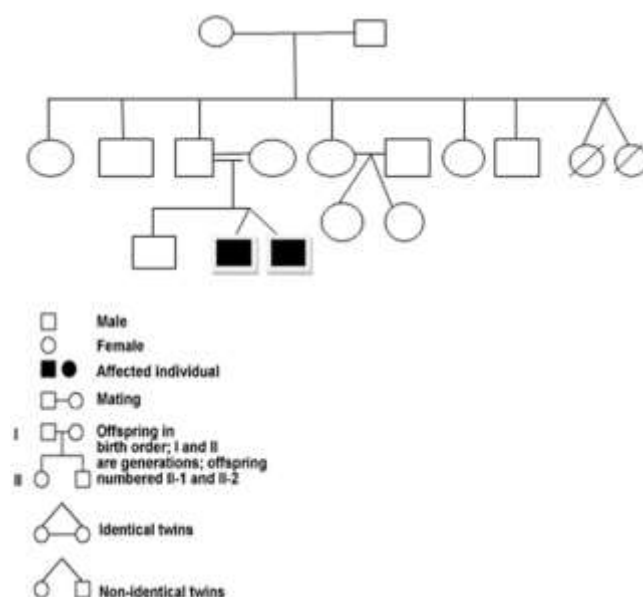


Figure 1 Pedigree chart of three generations.

Speech and language evaluation

Detailed Speech and Language investigation included a structured interview with the parents, oral peripheral examination, clinical interaction with the patients and administration of relevant tests. Case history revealed delayed motor and Speech and Language milestones. During the clinical assessment, they were constantly restless, appeared disinterested and were easily distracted. Chief behaviors observed were lack of attention, hyperactivity, low sitting tolerance, inconsistent eye contact, unusual behaviors such as Hyperactivity, Excessive shouting, head banging, rolling on the floor, fidgeting, vacant staring, non-meaningful laughter, presence of stereotypical behavior in terms of hand flapping, presence of self-injurious behavior such as hitting his head. He was not imitating actions, behaviors and single step commands. He was dependent for Activities of Daily Living (ADL). Both the patients' mode of communication was nonverbal with limited gestures. Prelinguistic skill assessment revealed poorly developed eye contact, attention span and eye hand coordination. He was able to comprehend family members and his expression for needs was through crying.

A comprehensive Speech and Language assessment was carried out by administering several standardized tests such as REELS (Receptive Expressive Emergent Language Scale), M-CHAT-R (Modified Checklist for Autism in Toddlers-Revised) and CARS (Childhood Autism Rating Scale) For both the children, results of REELS showed Receptive Language Age (RLA) from 6-7 months, whereas Expressive Language Age was found to be at 4-5 months of age, suggestive of delay in Speech and Language. Results of M-CHAT-R indicated High risk of developing ASD. This test is completed by yes/no parental report where child failed in more than three of the 23 items and three of the six critical items. CARS consist of 14 domains which assesses behaviours associated with ASDs. The score of 30 and above confirms presence of symptoms of ASD whereas in this case, a total score 36 on CARS suggestive of moderate ASDs.

Diagnosis and treatment

Integration of results of the above tests revealed delay in speech and language along with moderately severe autism spectrum disorders. Based on the history collected from the patient's family, physical examination, findings of other disciplines and results of the standardized tests the twins were diagnosed as having Delayed Speech and Language secondary to Autism Spectrum Disorders.

The patients had undergone various therapies such as Occupational therapy (OT), Dietary advice and Stem cell therapy. In OT education and information were given to parents about sensory issues, physical activities to improve flexibility, muscle tone and postural strength. Multisensory inputs such as vestibular, proprioceptive, tactile, auditory and visual feedback were given to improve his arousal level and tolerance to problem solving skills. Motor planning was provided to improve manipulation of body when presented with appropriate challenges. In the dietary management a detailed diet chart with 1400 Kcal energy and 22 gm protein including 'Gluten free Casein free' diet was suggested.

Stem cell therapy

Testosterone estimation, PET-CT scan, MRI, EEG and blood test were conducted as a pre-surgical routine test. Neurosurgical treatment included Adult Autologous bone marrow derived MNC's transplantation. The procedure was as follows. The patient in supine position, local anesthesia was given in region of the right anterior superior iliac spine following which using a bone marrow aspiration needle, 80 ml of bone marrow was aspirated and collected in heparinized tubes and transported to the laboratory. In the neural tissue cultural laboratory the MNCs were separated by the density gradient method. The cells were sent for CD34 counts. The cells were transported back to the O.T. in a sterile cool container. The patient was put in a left lateral position and using a spinal needle the thecal sac punctured in the L4-L5 space. CSF obtained was sent for examination. The cells injected through the spinal needle. The needle was withdrawn after the cells were injected. Solumedrol 250 mg in 500 ml isolyte P was given intravenously during the injection. Total cost of the procedure was 2.5 lakhs per child. Improvements assured after Stem cell therapy are better tolerance for different foods and improved digestion, more adequate behaviour at home and as well as outside, Reduced or loss of fear of loud noises, strangers and bright colours, Improved verbal skills and writing skills, sustained attention span and better concentration and Improved self-care skills. There was no difference seen any of the domains such as language, cognition, behaviour, motor or social skills.

Discussion

Recent advances in stem cell research, gene therapy, genomics, and cancer biology have created unprecedented opportunities to create new treatments for human disease [17]. Though scientific interest in stem cell therapies for autism began from 1980's, there are no effective scientific evidences. As discussed by Geffner LF and Santacruz P stem cells demonstrate specific immunologic properties, which make individuals with ASDs as

promising candidates in the management when no other medical/ pharmacological or surgical treatment option available which goes to the brain and repair the damage [13]. Safety of the patient is assured under this condition. There are a few studies which have reviewed cellular/molecular abnormalities, potentially useful stem cell types and clinical trials on the use of stem cells in treating autism. Though these studies have shown improvement in communication of the individual with ASDs, a small sample size which becomes questionable. Improvement in Speech, Language and Communication shown as a result of Stem cell therapy should be evaluated by a qualified Speech Language Pathologist (SLP) by using validated, standardized scales. However, authors who used Intrathecal invasive route of administration reported its safety and efficient delivery of cells to brain, as transplanted cells could reach critical central nervous system areas through cerebrospinal fluid enhancing repair of damaged centers [18]. As discussed by Sharma A and Gokulchandran N FSC have marked improvement compared to other types of Stem cell treatment whereas the ethical consideration remains unanswered [15]. Currently, there are no published evidences to explain the effectiveness of repeated cell transplantation in ASD is not available which have undergone several clinical trials.

A position statement on stem cell therapy was released on 17th January 2020 [19]. It stated that psychiatric disorders including autism are combined rearrangements of both neurodevelopmental and neurodegenerative trajectories of brain and are polygenetic in origin. They actually are symptomatic manifestations of different pathogenetic processes about which scientific evidence is as yet inconclusive. Stem cells may have potential for regenerative medicine, but does not have a place in the current form of therapy in psychiatry. It also explains that till now no scientifically validated and scrutinized research is there which proves that stem cells are helpful in any psychiatric disorders including autism. In the published guideline of [20] there are indications for stem cell treatment and none of psychiatric disorders including autism are listed there as indicators. Considering all the above factors The Indian Psychiatric Society therefore strongly condemns the use of stem cell therapy in psychiatric disorders, particularly autism.

Conclusion

Considering the limitations of the procedure, for effects of cellular therapies in ASD treatment, more complete and exhaustive investigations and large trials will be needed in order to claim definitive results. Before recommending or adopting any intervention program, SLP should make sure that there are enough evidences for the increased successes rate of that particular intervention program.

References

- 1 Siniscalco D, Kannan S, Semprún-Hernández N, Eshraghi AA, Brigida AL, et al. (2018) Stem cell therapy in autism: Recent insights. *Stem Cells and Cloning: Adv Appl* 11: 55-67.
- 2 Kopetz PB, Endowed EDL (2012) Autism worldwide: Prevalence, perceptions, acceptance, action. *J Soc Sci* 8(2):

- 196–201.
- 3 American Psychiatric Association (2013) Diagnostic and statistical manual of mental disorders. 5th ed. Washington DC: American Psychiatric Association.
 - 4 Baio J, Wiggins L, Christensen DL, Maenner MJ, Daniels J, et al. (2018) Prevalence of autism spectrum disorder among children aged 8 years, autism and developmental disabilities monitoring network, 11 sites, united states, 2014. *MMWR Surveill Summ* 67(6): 1–23.
 - 5 Bolton P, Macdonald H, Pickles A, Rios P, Goode S, et al. (1994) A case-control family history study of autism. *J Child Psychol Psychiatry* 35(5): 877–900.
 - 6 Bailey A, Le Couteur A, Gottesman I, Bolton P, Simonoff E, et al. (1995) Autism as a strongly genetic disorder: evidence from a British twin study. *Psychol Med*. 25(1): 63–77.
 - 7 Oberman LM, Rotenberg A, Pascual-Leone A (2015) Use of transcranial magnetic stimulation in autism spectrum disorders. *J Autism Dev Disord* 45(2): 524–536.
 - 8 Thibaut F (2017) New perspectives in autism spectrum disorders. *Dialogues Clin Neurosci* 19(4): 323.
 - 9 Rossignol DA, Bradstreet JJ, Dyke VK, Schneider C, Freeddenfeld SH, et al. (2012) Hyperbaric oxygen treatment in autism spectrum disorders. *Med Gas Res* 2(1):16.
 - 10 Sharma SR, Gonda X, Tarazi FI (2018) Autism spectrum disorder: Classification, diagnosis and therapy. *Pharmacol Ther* 190: 91–104.
 - 11 Mahla RS (2016) Stem cells applications in regenerative medicine and disease therapeutics. *Int J Cell Biol* 1-24.
 - 12 GIOSTAR-Global Institute of Stem Cell Therapy And Research.
 - 13 Geffner LF, Santacruz P, Izurieta M, Flor L, Maldonado B, et al. (2008) Administration of autologous bone marrow stem cells into spinal cord injury patients via multiple routes is safe and improves their quality of life: Comprehensive case studies. *Cell Transplant* 17(12): 1277-1293.
 - 14 Khan A, Parveen N, Mahaboob V, Rajendraprasad A, Ravindraprakash H, et al. (2008) Safety and efficacy of autologous bone marrow stem cell transplantation through hepatic artery for the treatment of chronic liver failure: A preliminary study. *Transplant Proc* 40(4): 1140-1144.
 - 15 Sharma A, Gokulchandran N, Sane H, Nagrajan A, Paranjape A, et al. (2013) Autologous bone marrow mononuclear cell therapy for autism: An open label proof of concept study. *Stem Cells Int* 1-13.
 - 16 Bradstreet JJ, Sych N, Antonucci N, Klunnik M, Ivankova O, et al. Efficacy of fetal stem cell transplantation in autism spectrum disorders: an open-labeled pilot study. *Cell Transplant* 23(1 Suppl): S105–S112.
 - 17 Positions and statements. International Society for Stem Cell Research.
 - 18 Sharma A, Gokulchandran N, Chopra G, Kulkarni P, Lohia M, et al. (2012) Administration of autologous bone marrow-derived mononuclear cells in children with incurable neurological disorders and injury is safe and improves their quality of life. *Cell Transplant*. 21(Suppl 1): S79–S90.
 - 19 Statement of stem cell therapy Indian psychiatric society on 17th January 2020.
 - 20 National Guidelines for Stem Cell Research (2013)